

## Total Tear Acl and Partial Tear Pcl in Football Athletes at Semarang City Hospital

Supradi

---

### Article Info

#### Article history:

Accepted: 30 Oktober 2020

Published: 1 December 2024

---

### Keywords:

Anterior Cruciate Ligament (ACL)

Fisioterapi

TENS, CRYOTHERAPI

SWT

Terapi Latihan

---

### Abstrak

*This study aims to determine the role of physiotherapy on the handling of post-operative ligament and determine through TENS, CRYOTHERAPI, SWT physiotherapy and exercise therapy (TL) in overcoming problems in ACL injuries. To find out from an injury in need assessment of the history of the disease, either history or examination. Well directed anamnesis thorough examination can be obtained a proper diagnosis. Examination was conducted in order to determine the existing problems in athletes postACL surgery, prepare therapeutic purposes and determine appropriate modalities. Screening measures include anamnesis, physical examination of a specific examination is the subjective examination and objective examination. Furthermore, the implementation of physiotherapy by means of TENS, CRYOTHERAPI, SWT, which is away of useful electrical energy to stimulate the nervous system through the skin surface and proven effective for reducing various types of pain. The conclusion of this study was: 1) Provision of TENS in the case of post ruptured anterior ligament carciatum aims to reduce pain through the mechanism of segmental and 2) a reduction in pain after treatment action for six times. Exercise therapy can provide pain reduction effect, both directly and break the cycle of pain spasm → pain. Light and movement will slowly stimulate proprioceptor which is the activation of large diameter afferent fibers. Granting Therapeutic Exercise in the case of post reconstruction craciatum anterior ligament which is to improve balance and improve muscle strength.*

*This is an open access article under the [Lisensi Creative Commons Atribusi- BerbagiSerupa 4.0 Internasional](https://creativecommons.org/licenses/by-sa/4.0/)*



---

### Corresponding Author:

Supradi

---

## 1. INTRODUCTION

Physical health and strength are one of a number of absolute requirements that a football athlete must have, considering that the severity of training and body contact between players is based on physicality. Therefore, a series of physical activities are carried out every day in the form of running, pushups, sit ups, pull ups, kicking the ball, dribbling the ball. It is not uncommon for a series of practices and matches to cause physical injury. Physical injuries can result in disruption of the musculoskeletal system which includes muscles, bones, joints, tendons, ligaments and connective tissue that supports and binds tissues and organs together (Spinder & Rick, 2007). One of the injuries resulting from a series of activities is anterior cruciate ligament (ACL) rupture (Spinder & Rick, 2007).

Rupture is tearing or tearing of tissue resulting from trauma (Dorland, 2002). The anterior cruciate ligament (ACL) is one of the four main ligaments in the knee that connects the tibia and femur bones. The main function of this ligament is to prevent the tibia bone from shifting forward from the femur bone and to control the rotational movement of the knee. Therefore, ACL rupture can cause the knee joint to become unstable so that the tibia bone can move freely (Dorland, 2002).

Anterior cruciate ligament (ACL) rupture often occurs in sports activities which basically involve squatting, twisting, stopping movements and jumping. Based on research

by Kaiser (Hewet & Timoty, 2007) in sports such as football, baseball, basketball, and soccer and skiing, 78% of anterior cruciate ligament injuries accompany sports activities. Therefore, football players who carry out physical training activities which basically include high impact have a great tendency to experience anterior cruciate ligament (ACL) rupture (Hewet & Timoty, 2007).

#### 1. Formulation of the problem

Based on the problems that arise in cases of anterior craciatum ligament (ACL) rupture, the author formulates the problem as follows;

1. Is there an effect of CRYOTHERAPY on ACL injuries in football athletes?
2. Is there an effect of giving TENS on ACL injuries in football athletes?
3. Is there an effect of giving SWT on ACL injuries in football athletes?
4. Is there an effect of exercise therapy on ACL injuries in football athletes?

#### 2. Objective

##### 1. General purpose

To find out the role of physiotherapy in treating anterior cruciate ligament (ACL) injuries.

##### 2. Special purpose

- a. To find out whether there is an effect of giving cryotherapy on ACL injuries in football athletes?
- b. To find out whether there is an effect of giving TENS on ACL injuries in football athletes?
- c. To find out whether there is an effect of giving SWT on ACL injuries in football athletes?
- d. To find out whether there is an effect of exercise therapy on ACL injuries in football athletes

#### 3. Benefit

##### 1. For Hospital Institutions

Provide additional knowledge as well as references about the role of physiotherapy in treating anterior cruciate ligament injuries.

##### 2. For Physiotherapy

Provides guidelines and alternatives for physiotherapy management in conditions of anterior cruciate ligament injury using physiotherapy modalities which include Cryotherapy, Tens, Eswt and Exercise Therapy.

##### 3. For Students

As additional knowledge for students of the physiotherapy profession so they can apply treatment to sports injuries.

## 2. LITERATURE REVIEW

### A. Definition

#### 1. Anterior Cruciate Ligament (ACL)

*Anterior cruciate ligament* (ACL) is one of the four main ligaments in the knee that connects the tibia and femur bones. The main function of this ligament is to prevent the tibia bone from shifting forward from the femur bone and to control the rotational movement of the knee. Therefore, an ACL rupture can cause the knee joint to become unstable so that the tibia bone can move freely. (McMillan, 2013).

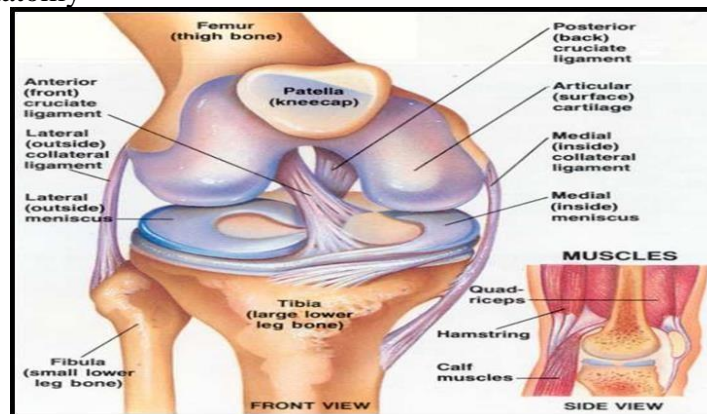
ACL rupture is a tear of the anterior cruciate ligament which causes the knee joint to become unstable so that the tibia bone shifts freely. ACL ruptures often occur in high-impact sports, such as football, futsal, volleyball, tennis, badminton, basketball and other sports such as martial arts (McMillan, 2013). Most ACL injuries require surgery. The standard ACL reconstruction surgery that is

commonly used is the arthroscopic technique (Jhun, MS., 1999).

Rupture is tearing or tearing of tissue resulting from trauma (Dorland, 2002). The anterior cruciate ligament (ACL) is one of the four main ligaments in the knee that connects the tibia and femur bones. The main function of this ligament is to prevent the tibia bone from shifting forward from the femur bone and to control the rotational movement of the knee. Therefore, ACL rupture can cause the knee joint to become unstable so that the tibia bone can move freely (Dorland, 2002).

Anterior cruciate ligament (ACL) rupture often occurs in sports activities which basically involve squatting, twisting, stopping movements and jumping. Based on research by Kaiser (Hewet & Timoty, 2007) in sports such as football, baseball, basketball, and soccer and skiing, 78% of anterior cruciate ligament injuries accompany sports activities. Therefore, football players who carry out physical training activities which basically include high impact have a great tendency to experience anterior cruciate ligament (ACL) rupture. (Hewet & Timoty, 2007)

## 2. Anatomy



## 3. Etiology

A very common mechanism encountered when an ACL rupture occurs is a combination of a sudden stopping movement of the leg accompanied by a sudden twisting movement of the knee. When the ACL is torn, the sufferer feels that the knee is coming out of joint and often hears a very loud sound. If the sufferer tries to stand, they usually feel unstable and eventually give up. The knee usually becomes swollen, very painful, and difficult to move. (Edwards, 2010).

## 4. Pathophysiology

The ACL prevents anterior translation of the tibia towards the femur and functions to minimize rotation of the tibia. A secondary function of the ACL is to prevent valgus and varus positions of the knee, especially during extension. ACL injury causes changes in knee kinematics. Related to the pathology that occurs, delaying ACL reconstruction can result in osteoarthritis. Approximately 15% of ACL rupture cases undergo Total Knee Replacement (TKR) (Maguire et al., 2012).

The ACL receives blood supply from the middle genualate artery, so that if the ACL ruptures, hemarthrosis will occur. However, despite its intra-articular location, the ACL is extra synovial because it does not have wound healing substances, so if an ACL rupture occurs it will be difficult to heal by itself (Brukner & Khan, 2011).

## 5. Clinical signs and symptoms

Post-operative ACL rupture sufferers encounter various signs and symptoms, namely pain on the outside and behind the knee, hemarthrosis caused by ligament

bleeding, and most often there is a "pop" sound from the knee and the knee feels loose/unstable. (Brukner & Khan, 2011).

#### 6. Differential diagnosis

The differential diagnosis for cases of ACL rupture is Patellofemoral Dysfunction. Front knee pain, or what is usually called patellofemoral pain, is related to dysfunction of the patellofemoral joint. Patellofemoral pain can describe many conditions associated with patellofemoral dysfunction, including patella malalignment syndrome, chondromalacia patellae, and patellar subluxation or dislocation. Pain in the patellofemoral area can be caused by trauma or may be caused by overuse. After surgery on the hip, knee or ankle, mechanical changes usually occur in the lower extremities, causing pain in the patella-femoral area. The second is Medial Collateral Ligament Injury (MCL). Things to pay attention to in MCL injuries are similar to those of ACL. Currently, MCL injuries receive less attention because MCL uses nonoperative management and because MCL is often associated with ACL injuries, which receive more attention. Several studies suggest that movements performed earlier in nonsurgical management produce better results in grade III MCL injuries. The third is Posterior Cruciate Ligament Injury (PCL). Injuries to the Posterior Cruciate Ligament (PCL) are uncommon injuries in athletics. (Maguire et al., 2012).

#### 7. Case study management

##### a. Patient identity

- Name: Fajar Setyadi
- Age: 20 Years
- Male gender
- Address: Jl. Papandayan no 1 Semarang
- Occupation: Football Athlete

##### b. Medical diagnosis

Total ACL Tear and Partial PCL Tear Genu Dextra

##### c. History of illness

- Main Complaint: The patient feels pain in the inner right knee area, difficulty walking and going up and down stairs.
- Current illness history: at the time of the match patient perform a celebration that causes a wrong landing.
- Past medical history: -

##### d. Vital Signs

- Blood pressure: 120/80 mmHg
- Pulse: 80x/minute
- Respiration: 20x/minute
- Temperature: 36

##### e. Physical examination

###### 1) Inspection

###### (a) Static:

- Oedema was seen in the right knee
- It looks like the right patella is higher than the left knee
- You can see redness on the front of the right knee.

###### (b) Dynamic:

- The patient was seen walking with a limp and in pain
- The patient is seen walking with a bent posture.

###### (c) Palpation:

- the presence of edema and pitting edema, the presence

of local tenderness and temperature on the knee front left

f. Specific inspection


1. Hyperextension test: (+)
2. Slide drawer test (+)
3. Valgus test (+)
4. Varus test (+)
5. Appley's test (+)

g. Special Inspection

1. PFGD:
  - Active: - Flexi – Not Full ROM, Pain (+), Extension – Not Full ROM, Pain (+)
  - Passive: Flexi: Not Full ROM, Pain (+) Elastic, Extension: not full ROM, Pain (+) Hard
  - Isometrics: Against minimal resistance Flexi and Extension Pain (+)
2. VAS : - Still: 0 Move: 70mm Press: 50mm



3. GONEOMETER: Active: S: 0°-0-95°, Passive: S: 3°-0-110°



4. MMT:
  - Flexor: Dextra: 3 Sinistra: 5
  - Extensors: Dextra: 3 Sinistra: 5

h. Physiotherapy Diagnosis

1. Impairment: Pain with movement, pressure on the right knee, difficulty walking and going up and down stairs, limited range of motion in the joints and decreased muscle strength.
2. Functional Limitation: disturbed activity and unable to participate in training.
3. Participation restriction: activities are disrupted and unable to participate in playing practice

- i. Physiotherapy Goals
  - Short term: Reduces pain, reduces swelling, trains to walk, trains to go up and down stairs, increases muscle strength, increases range of motion of joints.
  - Long term: Continuing from short term goals by providing physiotherapy modalities.
- j. Physiotherapy Action Plan
  - CRYOTHERAPY
  - TENS
  - SWT
- k. Physiotherapy Intervention
  - CRYOTHERAPY SOP
    - Patient position: the patient lies on his back with his legs semi-flexed
    - Tool position: transducer is pointed at the injured knee area
    - Dosage: intensity: 7, duration 15 minutes sagittal direction
  - TENS SOP
    - Patient position: patient lies supine
    - Tool position: Using 4 pads Flow: intermittent  
Frequency: 2500Hz Amf: 50Hz  
Modulation Frequency: 10Hz Program Modulation: 6/6
  - SWT SOP
    - Patient position: supine with knees semi-flexed
    - Tool position: transducer is directed at the center of the pain point or trigger point. Intensity: 2  
Frequency: 10  
Total: 1000/10x shot count Flow: Burst
- l. Evaluation
  - After undergoing 2x therapy, there was a change in the patient's condition, pain decreased, joint range of motion increased and muscle strength increased. Even though the patient walks, he still uses crutches and is under supervision.

### 3. RESULTS AND DISCUSSION

#### 1. Results

After undergoing 2x therapy, there was a change in the patient's condition, pain decreased, joint range of motion increased and muscle strength increased. Even though the patient walks, he still uses crutches and is under supervision.

By inspecting the object based on existing clinical evidence, many factors influence the level of analytical ability so that relative truth is achieved based on theoretical foundations, clinical experience and valid and objective parameters. In connection with this, the writer is aware of the deficient condition.

Regarding this matter, it is very possible that there will be errors in interpretation, due to the many variables that refer to this matter, the writing can start from very simple things according to the author's knowledge and other factors that support the discussion of this case. The following are the results of research regarding the results of therapeutic procedures for six times post reconstruction of the Anterior Cranium Ligament (ACL) of the right knee with tens and therapy (Kurt, S & Wright, R. 2007).

#### 2. Discussion

TENS (Transcutaneous Electrical Nerve Stimulation) TENS is a modality with

low electrical energy that is delivered to the skin via electrodes placed over the area experiencing pain. The electric current that can be given by TENS can stimulate large diameter sensory neuron cells to enter the gate in the substantia gelatinosa first and inhibit small diameter nociceptor cells from providing information to the brain, so that painful stimuli do not reach the brain and reduce pain (Hardjosworo, 2014)

The physiotherapy modality is Transcutaneous Electrical Nerve Stimulation (TENS) which uses electrical energy to stimulate the nervous system through the surface of the skin in connection with pain modulation. Giving TENS in cases of post rupture of the anterior cruciate ligament aims to reduce pain through a segmental mechanism. TENS will produce an analgesic effect with road activates A beta fibers which will inhibit nociceptive neurons in the dorsal horn of the spinal cord. This theory refers to the gate control theory (Gate Control Theory) that the gate consists of inhibitory interneurons known as the substantia gelatinosa and which are located in the posterior horn and T cells which relay information from higher centers. Impulses from large diameter afferent fibers will close the gate and block impulse transmission from nociceptor afferent fibers so that pain is reduced (Parjoto, 2006).

**Exercise Therapy** The effect of exercise therapy is that it can have a pain reduction effect, both directly and breaking the pain cycle of pain spasm. Light and slow movements stimulate the proprioceptor which is the activation of large diameter afferent fibers. The exercise therapy that can be given is strengthening, which is an exercise that aims to strengthen the muscles. In this case, quadriceps bands and hamstring setting exercises are carried out which are useful for increasing the strength of the quadriceps and hamstring muscles. This exercise is an isometric strengthening exercise where the muscles contract without changes in muscle length or joint movement. Besides being able to increase muscle strength, the effect of this exercise is to pump blood vessels back, so that metabolism runs smoothly and can reduce swelling (Bjordal et al. 2007).

Exercise therapy can improve balance and increase muscle strength. Exercise therapy in cases of post anterior cruciate ligament reconstruction, namely improving balance and increasing muscle strength. The training given is training using the Closed kinetic chain method, which is a technique of Proprioceptive Neuromuscular Facilitation (PNF) which uses optimal isometric contraction of the shortened antagonist muscle group followed by relaxation of the muscle until LGS is added. Hold relax is carried out with the aim of increasing muscle strength and balance. In the hold relax procedure, there is initially an isometric contraction movement against resistance, followed by relaxation as a result of autogenic inhibition, where the Golgi tendons will inhibit muscle tension so that stretching of shortened muscle tissue is easier to do (Edler, et al., 2008)

The stretching or stretching method can be selective and not only on the tendons, but also reaches the permysium, epysium and ensonysium. Meanwhile, to carry out stretching, it must be in the correct position and with a clear voice or command that is not loud, so that the implementation can take place well and the muscles that are stretched or contracted will relax more easily. The more the muscles become relaxed, the more a person can move fully without feeling pain. Stretching is a general term used to describe or describe several treatment maneuvers aimed at prolonging pathological shortening of the soft tissue structure and increasing LGS (Buschbacher. 2002).

Active and passive ROM exercises are joint range of motion exercises carried out with and without the use of assistance. This exercise must be carried out immediately in patients after anterior cruciate ligament (ACL) reconstruction, especially to keep the muscles intact as an athlete because the expected goal of this



patient is to return to functional activities as a soccer athlete. Therefore, the author provides intervention by combining the provision of TENS modality therapy and the Quadriceps Bents Exercise, Hamstring Setting Exercise, Straight Leg Raise Exercise, Balance training programs. When the intervention is carried out, the patient can follow the instructions properly and correctly, the patient has a high desire to recover and return to his best performance. However, patients who are slightly traumatized are given training, so the author provides a personal approach to the patient. Finally, the patient's fear gradually disappeared (Beaupre et al, 2005).

#### 4. CONCLUSIONS AND RECOMMENDATIONS

##### 1. Conclusion

*Anterior cruciate ligament* (ACL) is one of the four main ligaments in the knee that connects the tibia and femur bones. The main function of this ligament is to prevent the tibia bone from shifting forward from the femur bone and to control the rotational movement of the knee. Therefore, an ACL rupture can cause the knee joint to become unstable so that the tibia bone can move freely.

Patient name: Fajar Setyadi, age: 20 years, address: Jl.papandayan no 1 Semarang, Occupation: Football Athlete, diagnosis: Total ACL tear and PCL Genu Dextra partial tear. After undergoing 2x therapy, there was a change in the patient's condition, pain decreased, joint range of motion increased and muscle strength increased. Even though the patient walks, he still uses crutches and is under supervision.

##### 2. Suggestion

Patient: Order ACL reconstruction surgery immediately.

#### 5. BIBLIOGRAPHY

- Arthroscopi [online]*. Jakarta, Orthopedi Rumah Sakit Mitra Kemayoran; 2010. Diakses 10 desember 2021).
- Beaupre, LA., Jones, A., & Saunders, LD. 2005. Best Practices for Elderly Hip Fracture Patients A Systematic Overview of the Evidence. *J Gen Intern Med*; 20:1019–1025.
- Bjordal, JM., Klovning, A., Ljunggren, AE., & Slordal L. 2007. Short-Term Efficacy Of *Pharmacotherapeutic* Interventions In Osteoarthritic Knee Pain: A Meta-Analysis Of Randomised Placebo-Controlled Trials. *Eur J Pain*. Book Company.
- Brukner, P & Khan, K. 2011. *Clinical Sports Medicine*. 2nd Ed. New York: The McGraw-Hill *Buschbacher*. 2002. Practical Guide to Musculoskeletal Disorders : Diagnosis and Rehabilitation. Second edition. USA. Pp:76-84
- Dorland. 2002. Kamus saku kedokteran edisi 28. Jakarta : Buku kedokteran EGC Edwards R., 2010. *Rekonstruksi Kerusakan Anterior Cruciate Ligament (ACL) dengan*
- Hardjosworo, SA., 2014; Penanganan Cedera Olahraga [online]. Tangerang: Sport Clinic Bintaro International Hospital; [diakses 11 desember 2021]. Available from: URL: [www.rspremierbintaro.com/healthinfo/DefaultEvent.aspx?id=10](http://www.rspremierbintaro.com/healthinfo/DefaultEvent.aspx?id=10)
- Hewet & Timothy. 2007. Understanding and preventing Noncontact ACL injuries. United of America : American Orthopaedic Society for Sport Medicine <http://www.rumahsakitmtrakemayoran.com/rekonstruksikerusakan-anterior-cruciate-ligament-acl-dengan-arthroskopi/>.
- Jhun, MS., 1999. Patellofemoral Pain Syndrome : a review and guidelines for treatment. USA. *Journal of the American Academy of Family Physician*. (diakses: 15 desember 2021)
- Kurt, S & Wright, R. 2007. Anterior Cruciate Ligament (diakses 11 desember 2021)



<http://www.nejm.org/doi/full/10.1056/nejmcp0804745>

McMillan, S. 2013. *Anterior Cruciate Ligament Reconstruction*. Burlington: Lourdes Medical Associates Professional Orthopaedics